

# Change in clinical indices following laser or scalpel treatment for periodontitis: A split-mouth, randomized, multi-center trial.

David M. Harris, PhD<sup>a</sup>, Dawn M. Nicholson, DDS<sup>b</sup>, Delwin McCarthy, DDS<sup>b</sup>,  
Raymond A. Yukna, DMD, MS<sup>c</sup>, Mark A. Reynolds, DDS, PhD<sup>d</sup>,  
Henry Greenwell, DMD, MSD<sup>e</sup>, James Finley DMD, MS<sup>f</sup>, Thomas K. McCawley, DDS<sup>g</sup>,  
Pinelopi Xenoudi, DDS, MS<sup>c</sup> Robert H Gregg II, DDS<sup>b</sup>

- a. Bio-Medical Consultants, Inc., Paradise CA
- b. Institute for Advanced Laser Dentistry, Cerritos CA
- c. University of Colorado, School of Dental Medicine, Denver CO
- d. University of Maryland, Dental School, Baltimore MD
- e. University of Louisville, School of Dentistry, Louisville KY
- f. Private Practice, Lafayette LA
- g. Private Practice, Fort Lauderdale FL

## ABSTRACT

Data are presented from a multi-center, prospective, longitudinal, clinical trial comparing four different treatments for periodontitis, (1) the LANAP™ protocol utilizing a FR pulsed-Nd:YAG laser; (2) flap surgery using the Modified Widman technique (MWF); (3) traditional scaling and root planing (SRP); and (4) coronal debridement (CD). Each treatment was randomized to a different quadrant. Fifty-one (54) subjects were recruited at five centers that included both private practice and university-based investigators. At 6-months and 12 months post-treatment the LANAP™ protocol and MWF yielded equivalent results based on changes in probing depths. The major difference observed between the two procedures was that patients reported significantly greater comfort following the LANAP™ procedure than following the MWF ( $P < 0.001$ ). There was greater reduction in bleeding in the LANAP™ quadrant than in the other three at both 6 and 12 months. Improvements following SRP were better than expected at 6 months and continued to improve, providing outcomes that were equivalent to both LANAP™ and MWF at 12 months. The improvement in the SRP quadrants suggests the hypothesis that an aspect of the LANAP™ protocol generated a significant, positive and unanticipated systemic (or trans-oral) effect on sub-gingival wound healing.

## INTRODUCTION

Periodontitis is a major national health problem and is the primary cause of tooth loss in adults. The primary etiologic factor in periodontitis is bacterial plaque, which results in an inflammatory lesion in the adjacent tissue leading to progressive destruction of the supporting periodontal tissues. The primary goal of current therapy is to control the inflammatory lesion in such a way that progressive destruction of the periodontium is arrested. A number of therapeutic approaches have been successful in achieving this goal. Most of these involve extensive therapeutic intervention, often combined with surgical management of the tissues. The major nonsurgical therapeutic approach involves mechanical Scaling and Root Planing.

In 1996 American Dental Technologies ran a clinical trial at the University of Texas, HSC in San Antonio to establish safety and effectiveness of laser sulcular debridement<sup>1</sup>. They were seeking clearance from the FDA to allow the dentist to insert the tip of an optical fiber connected to a pulsed Nd:YAG laser into the periodontal sulcus in the treatment of periodontitis. In 1999 they obtained FDA market clearance for "*Laser Sulcular Debridement (removal of diseased or inflamed soft tissue in the periodontal pocket) to improve clinical indices including gingival index, gingival bleeding index, probe depth, attachment loss, and tooth mobility.* Section

510(k), No. K961269.” A second similar study at the University of Louisville Dental School confirmed the results<sup>2</sup>.

LANAP™ incorporates Laser Sulcular Debridement into a comprehensive step-by-step surgical procedure that also includes use of the Ultrasonic scaler, high-speed handpiece, and special hand instruments. The two general dentists who had developed LANAP™ first published their private practice case reports of patients treated with the Protocol showing improvement in clinical indices and some evidence suggesting bone and ligament regeneration<sup>3-6</sup>. They were challenged to produce results from more rigorously conducted studies so they sponsored an independent analysis of retrospective results, that we reported here a dozen years ago<sup>7</sup>.

The primary outcome variable of that analysis was probing depths as recorded in the patient records. Inclusion criteria were (1) received LANAP™ for advanced periodontitis and (2) provided a complete chart of probing depths at the time of treatment and follow up data from 3 to 36 months post-LANAP™. The report included 65 anonymous subjects from the private practices of Robert H. Gregg II, DDS and Delwin K. McCarthy, DDS, Cerritos, CA; Leigh E. Colby DDS, Eugene, OR; and Lloyd V. Tilt DDS, Ogden, UT. Results indicated a period of continued reduction in pocket depths over the first year, a period of healing, and long term stability of results out to 3 years. Pocket depth reductions were as good as results in other published University-based studies. There was also evidence of bone regeneration<sup>8</sup>.

A controlled human tooth extraction study examined the microscopic structure of the post-LANAP™ tissues<sup>9,10</sup>. Teeth that were scheduled for removal were treated with LANAP™, allowed to heal for three months and extracted. Teeth were sectioned, stained and examined in the microscope to test the hypothesis of regeneration. The study results showed growth of new bone and new connective tissue. What was most significant was that at three months the post-LANAP™ healing process appeared to be regenerating the tissue structure back to its normal configuration, something that seldom happens following gum surgery. Based on these results FDA granted MDT market clearance to Millennium Dental Technologies, Inc. for the claim: *“Laser Assisted New Attachment Procedure (LANAP™) [induces] cementum-mediated periodontal ligament new-attachment to the root surface in the absence of long junctional epithelium. FDA 510(k) K030290.”*

A research group at Harvard School of Dental Medicine conducted a second human extracted human tooth study but this time they waited nine months after LANAP™ for additional healing. Their 2012 report in the *International Journal of Periodontics & Restorative Dentistry*<sup>11</sup> “provides evidence that LANAP™ therapy can induce periodontal regeneration.” A recent publication from this group reports probing depths at nine months post-LANAP.<sup>12</sup> In the DISCUSSION these data from a whole mouth LANAP™ procedure are compared to the present probing depths following LANAP™ in a split mouth design.

These past studies all examined LANAP™ in isolation. The purpose of the present study was to compare the efficacy of the LANAP™ protocol with the current standard Modified Widman Flap surgery for the treatment of advanced periodontitis.

We report here some preliminary results from a multi-Center clinical trial conducted by The Institute for Advanced Laser Dentistry:

*“A Multi-Center Single Blind Study of the Laser Assisted New Attachment Procedure Compared to Scaling and Root Planing Alone, Modified Widman Flap Surgery, and Coronal Debridement Alone in the Treatment of Chronic Periodontitis”*

The only variables analyzed at this time are probing depth, bleeding, and discomfort. A more complete report is in preparation.

## METHODS

**Study design.** The trial was conducted at five domestic performance sites including three University-based Dental Schools and two private practices. The protocol was reviewed and approved by the IRB having jurisdiction over each site and the Trial was registered with ClinicalTrials.gov. Liza Burns Assoc, an independent CRO, monitored the trial.

The operators and examiners at each center were trained and calibrated. The investigator administering the treatments did not conduct clinical measurements. A blinded examiner conducted all clinical measurements.

Each subject was entered into the study based upon an initial Screening Evaluation certifying the following conditions:

- Advanced, chronic periodontitis.
- At least 4 sites per quadrant with PD  $\geq$  5mm and 2 sites with PD  $\geq$  7mm and Bleeding on Probing (BOP).
- Clinical and/or radiographic evidence of subgingival calculus in each quadrant.
- No more than one missing tooth per quadrant, excluding 3rd molars.
- Satisfactory occlusion on both sides of the jaw.
- No current restorative or endodontic treatment needs.
- No history of periodontal surgery and no subgingival scaling instrumentation including scaling and root planing, regular periodontal maintenance procedures or any subgingival cleaning < 12 months prior to Baseline examination.
- Non-smokers, not taking or using any nicotine product.
- 25-75 years of age and in good general health.
- The subject understood and signed informed consent.

Four treatments were randomly assigned to the four dental quadrants, UR, LR, UL and LL, in each subject.

Coronal Debridement (CD). Subjects were treated first with full-mouth debridement (CD) of the coronal aspect of each tooth above the gum line using an ultrasonic scaler and hand instruments. The smoothness was verified with an explorer. At baseline each patient received limited occlusal adjustment in all quadrants. Following this the CD quadrant was finished and the three other quadrants received additional treatments.

Scaling and Root Debridement (SRP). This quadrant received a complete subgingival debridement with an ultrasonic scaler and root planing with curettes, until the surfaces of the roots feel calculus free and smooth and hard with an explorer. Sites were instrumented to the therapeutic endpoint. Clinical care was taken to assure that the standard mechanical instrumentation did not result in a surgical procedure, and that the site was not over-instrumented to the detriment of existing levels of connective tissue attachment.

### Modified Widman Flap (MWF).

The MWF is a standard three incision approach with full-thickness flap reflection to gain access to the root surfaces and crestal bone. Ultrasonic and hand curette debridement, scaling, and root planing was performed to the point of visual cleanliness of the roots and any associated bony defects. Some minor osteoplasty for improved flap adaptation and primary closure was employed. The flaps were approximated around the

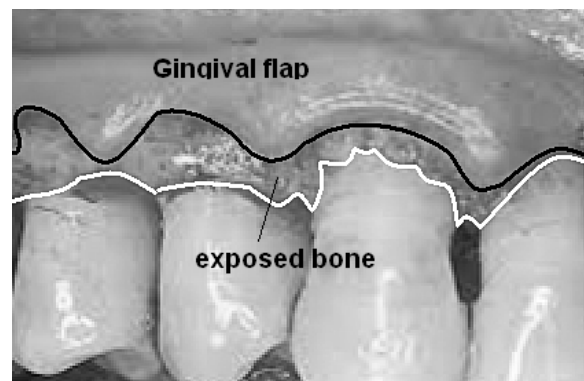


Figure 1. Modified Widman Flap (MWF) after debridement and prior to suturing. The scalloped shape of the retracted gum tissue follows the shape of the gingival margin.

necks of the teeth with sutures. Periodontal dressing was not placed.

**LANAP™.** The LANAP™ protocol is a step-by-step surgery for treating periodontitis that requires training & proficiency certification on the PerioLase® MVP-7™ laser and licensure to perform the LANAP™ protocol. It is a minimally invasive, well-defined procedure, that involves surgical removal of the sulcular epithelium, modification & osteoplasty of bone and perforation of the PDL using piezoelectric bone cutting tips, and wound closure via a thermogenic stable fibrin gel clot, without scalpel or sutures. A modified LANAP™ procedure was used to accommodate the split mouth, 4-quadrant design. The steps of the procedure are illustrated in Figure 2. A more detailed description of the LANAP™ procedure is provided elsewhere.<sup>5,12</sup>

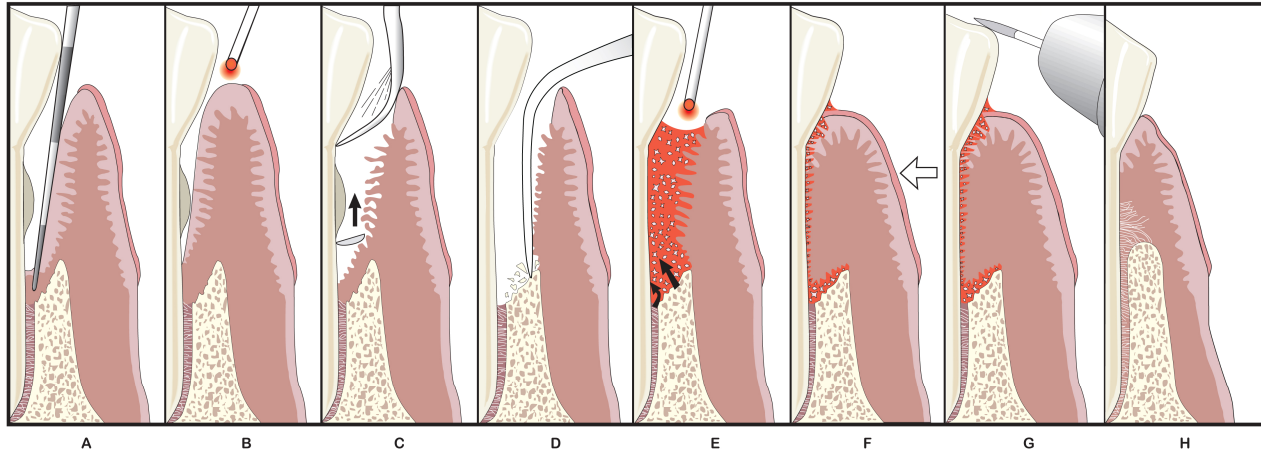


Figure 2. Overview of the LANAP procedure. (A) Pocket depths are measured with a perio probe. (B) Pass 1 with the laser vaporizes diseased tissue. (C) The use of an ultrasonic scaler and hand instruments remove root accretions. (D) Bone is modified and (E) Pass 2 with the laser forms a fibrin clot. (F) Reattachment to root surface is achieved with a stable fibrin clot at the gingival crest. (G) Occlusal trauma adjusted. (H) New attachment is regenerated (Yukan, Nevins)

This graphic is for illustrative purposes only and is not a technical representation of the LANAP® protocol. Usage without permission is prohibited. © 2011 MDT, Inc. © 2011 IALD. All rights reserved

**Statistical analysis.** Results were recorded by pocket for both probing depth and bleeding. Up to eight teeth per quadrant (treatment) and up to six pockets per tooth were candidates for analysis. Although three patients had data at six months but not at twelve months, for more accurate assessment of time trends this analysis only focuses on the 49 patients completing twelve months. Six month changes from baseline and 12 month changes from baseline were analyzed using analysis of variance for a mixed model, with the factors of patient and treatment and the nested variables of teeth within treatments and pockets within teeth. The final analysis considers pockets and teeth together for the overall error term, although treatment differences were tested against the patient by treatment error term. Tukey's HSD multiple comparisons were used for pair-wise comparisons of treatments.

Bleeding (Yes/No) was recorded for each pocket. Percents of pockets with bleeding were tabulated for all pockets for patients completing 12 months and were summarized by treatment and time. Six and twelve month data were stratified by pockets with or without baseline bleeding. To assess the significance of treatment differences, the percentages of pockets with bleeding were summarized by patient and treatment and changes from baseline were compared at six and twelve months using analysis of variance with the factors of patient and treatment. Tukey's HSD (honest significant difference) multiple comparisons were used for pair-wise comparisons of treatments.

Discomfort was measured on a visual analogue scale from zero to ten, recorded daily from Day one to Day 21 and then at Day 30. An aggregate score from Day 1 through Day 7 was also computed. Data were analyzed

using Friedman nonparametric tests for paired ranked data. An overall test among all four treatments was performed and then paired orthogonal comparisons were performed comparing CD to SRP, MWF to LANAP™, and Surgical (MWF, LANAP™) versus non-surgical (CD, SRP).

## RESULTS

**Demographics.** There were 54 patients included in the study, including 28 men and 26 women, but two were removed from the analysis for protocol violations. Three have not completed the 12 month analysis, basing the analysis of probing depth and bleeding on results for 49 patients treated with four treatments over the four quadrants of the mouth. Discomfort scores were recorded for 52 patients. Mean age was 47.9 years with a range of: 25-68 years.

**Laser Dosimetry.** An average of 2250 Joules of 1064nm laser energy was delivered to the LANAP™ quadrant with a range of 905J/Q to 5372J/Q. Individual performance sites ranged from 1699J/Q (Site 3) to 3718J/Q (Site 4).

Treatment	BL PD (mm)	N	Baseline	6 month	12 month	6-Mo Change	12-Mo Change
LANAP™	3-5	975	4.1 ± 0.9	3.1 ± 1.3	2.9 ± 1.2	1.1 ± 1.2	1.3 ± 1.3
	≥ 6	<b>327</b>	<b>7.2 ± 1.0</b>	<b>4.7 ± 1.9</b>	<b>4.3 ± 1.8</b>	<b>2.5 ± 1.8</b>	<b>2.9 ± 1.7</b>
MWF	3-5	943	4.1 ± 0.9	3.0 ± 1.2	2.8 ± 1.2	1.2 ± 1.1	1.3 ± 1.2
	≥ 6	<b>313</b>	<b>7.2 ± 1.0</b>	<b>4.3 ± 1.6</b>	<b>4.4 ± 1.6</b>	<b>2.9 ± 1.6</b>	<b>2.8 ± 1.6</b>
SRP	3-5	962	4.1 ± 0.8	3.1 ± 1.3	3.0 ± 1.3	1.0 ± 1.3	1.1 ± 1.3
	≥ 6	<b>330</b>	<b>7.3 ± 1.1</b>	<b>5.1 ± 2.0</b>	<b>4.6 ± 2.1</b>	<b>2.2 ± 1.9</b>	<b>2.7 ± 2.0</b>
CD	3-5	939	4.1 ± 0.8	2.9 ± 1.2	2.8 ± 1.2	0.8 ± 1.3	0.9 ± 1.5
	≥ 6	<b>292</b>	<b>7.3 ± 1.2</b>	<b>5.2 ± 2.2</b>	<b>5.2 ± 2.1</b>	<b>1.8 ± 1.8</b>	<b>2.1 ± 2.0</b>

Table 1. Summary of 6 month and 12 month changes (mean ± S.D.) in probing depth of pockets with baseline probing depth of 3-5mm and ≥ 6mm in 49 patients completing the study.

**Probing Depths.** Table 1 summarizes probing depth by treatment and time and Table 2 shows the results of the statistical analysis for pockets 6mm or greater at baseline. At six months, improvements in probing depth for treatment CD averaged 1.92mm compared to 1.98mm for SRP. This difference was not statistically significant, however when the CD result is compared to the improvements for MWF (1.57mm) and LANAP™ (1.89mm) the differences were statistically significant (P<0.01). The difference between MWF and SRP is close to achieving significance (P=0.06). The differences between SRP and MWF or LANAP™ were not statistically significant, and neither was the difference between MWF and LANAP™.

	6-Mo PD decr. Difference (mm)	P-value	12-Mo PD decr. Difference (mm)	P-value
LANAP™ VS MWF	-0.24	0.60	0.04	<b>0.99</b>
LANAP™ VS SRP	0.25	0.57	0.11	<b>0.95</b>
MWF VS SRP	0.49	0.06	0.06	<b>0.99</b>
LANAP™ VS CD	0.64	<b>0.01</b>	0.67	<b>0.01</b>
SRP VS CD	0.39	0.22	0.56	<b>0.03</b>
MWF VS CD	0.88	<b>0.01</b>	0.63	<b>0.02</b>

Table 2. ANALYSIS OF VARIANCE: Tukey's multiple comparisons of differences among treatments for pockets ≥ 6mm. At 6-Mo post-treatment LANAP™ and MWF are significantly different than CD. SRP continues to improve and by 12-Mo SRP, MWF and LANAP™ all are equivalent in Probing Depth reduction.

In a pair-wise comparison between two treatments a P-value of **0.99** means there is a 99% probability that they are the same. We can set the criteria for "equivalence" as P≥0.95. At 12 months LANAP™, MWF and

SRP are equivalent and all significantly different than CD. At 12 months, improvement in probing depth averaged 2.05 mm for CD, but this was statistically significantly less than the other three treatments: SRP (2.65 mm,  $p=0.03$ ), MWF (2.78 mm,  $p=0.02$ ) and LANAP™ (2.94 mm,  $p=0.01$ ). There were no statistically significant differences among SRP, MWF, and LANAP™ results.

Improvement from six to twelve months increased for CD, SRP, and LANAP™, but decreased slightly for MWF, although improvements for MWF were the largest of all treatments at 6 months. Also of interest is the observation the SRP results approached those for MWF and LANAP™ by the end of twelve months ( $P=0.99$ ), whereas at six months they were close to being statistically significantly less than MWF ( $P=0.06$ ). These are definitely anomalous data. We will want to know why the SRP quadrant improved dramatically.

### Bleeding

In patients with baseline bleeding (N=37) Tukey's HSD multiple comparisons shows a significant difference between CD and LANAP™ at both six and twelve

months. All other treatments had results intermediate to these results. In these patients, bleeding for the CD treatment improved 26% versus 34% for LANAP™ at six months ( $P=0.045$ ), and 24% versus 32% at twelve months ( $P=0.032$ ).

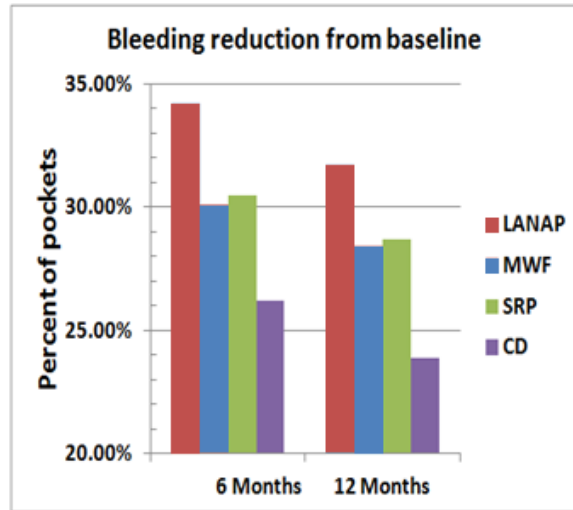


Figure 1. Reduction in the percent of sites that bled at baseline and when probed at six months and twelve months after treatment. The LANAP VS CD difference is significant at both time points

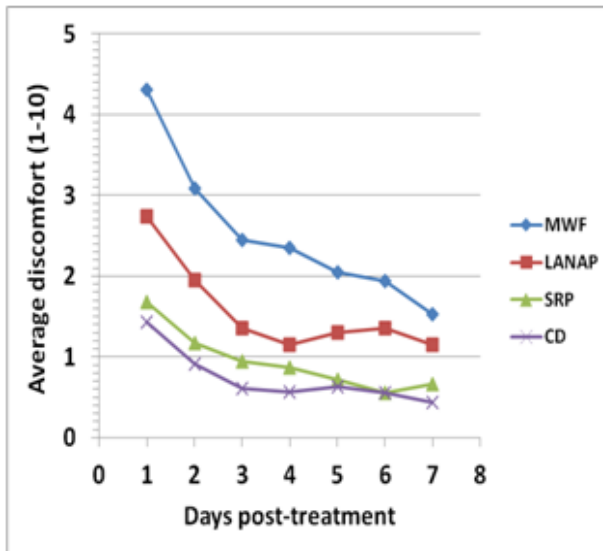


Figure 2. Patients estimated discomfort in each quadrant in a diary starting one day post-treatment. Plotted are average discomfort scores VS time for each treatment. LANAP VS MWF difference is significant as is Surgical VS non-surgical ( $p<0.001$ ).

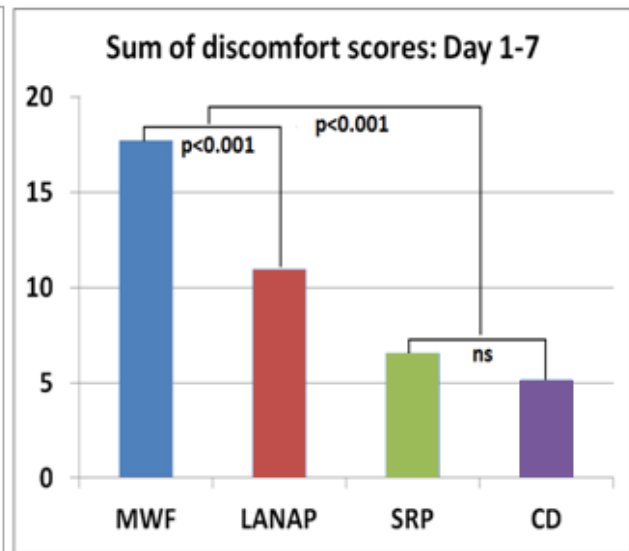


Figure 3. Discomfort scores were summed over days 1 through 7. LANAP VS MWF difference is significant as is Surgical VS non-surgical ( $p<0.001$ ).

**Discomfort**

Discomfort results are shown in Figures 2 and 3. On Day 1 LANAP™ had significantly less discomfort than WMF (P<0.001). Discomfort on Day 1 was significantly greater for the surgical treatments than for the non-surgical treatments (P<0.001). There was no difference between CD and SRP. These differences were also seen for the sum of the scores from Day 1 to Day 7. Median days to no discomfort were 5 for CD, 4.5 for SRP (no difference) and 11 for LANAP™ versus 14 for MWF (p=0.074). The Surgical versus non-surgical comparisons were again highly significant (p<0.001).

**DISCUSSION**

**Split-mouth VS Whole-mouth.** Dr. Marc Nevins and his group at Harvard School of Dental Medicine conducted a prospective trial of eight LANAP™-treated patients with periodontally infected teeth that were scheduled for extraction.<sup>11,12</sup> The histologic results were presented above. They have just published the 9-Mo changes in probing depth in this cadre of patients that we can compare to the current results.<sup>12</sup> We made adjustments of the LANAP™ protocol to accommodate the split-mouth design and this is the primary difference between the two groups. For the purpose of an accurate comparison the current study PD data have been resorted into the ≥ 5mm category and 0mm baseline pocket depths removed from the sample (Table 3).

The Nevins study had deeper baseline PDs: 4.52mm VS 3.85mm for the current study. Consequently, average PD reductions are slightly higher: 1.38 mm VS 1.14mm. For the deeper ≥5mm pockets baselines are essentially the same (6.45mm and 6.50mm) and the sample sizes are similar with 47 quadrants from the current study and 32 quadrants in the Nevins analysis. The mean probing depth reductions for ≥5mm pockets in the two studies are quite similar: 2.58 VS 2.53mm. A retrospective review of 44 private practice patients treated with whole-mouth LANAP™ measured average PD reduction in pockets with baseline PD ≥5mm to be 2.62mm, also in agreement.<sup>8</sup> This means that the split mouth design probably did not have a large influence on the clinical outcome of reduction in Probing Depths, at least in the LANAP™ quadrant.

	Present study: LANAP™ quadrant			Nevins, 2014	
	Baseline	6 months	12 months	Baseline	9 months
All pockets ≥ 1 mm					
Number of pockets	2044	2044	2044	930	930
Mean	3.85	2.91	2.71	4.52	3.14
SD	1.90	1.59	1.48	2.29	1.48
<b>PD reduction</b>		<b>0.94</b>	<b>1.14</b>		<b>1.38</b>
Pockets ≥ 5 mm					
Number of pockets	547	547	547	444	444
Mean	6.45	4.33	3.92	6.50	3.92
SD	1.20	1.78	1.73	2.07	1.54
<b>PD reduction</b>		<b>2.12</b>	<b>2.53</b>		<b>2.58</b>

Table 3. Comparison of pocket depth reductions (mm) in the LANAP™ quadrant (N=49) of the present split-mouth study with whole-mouth LANAP™ from the Nevins Study (N=8, 32 quadrants).

**LANAP™ VS MWF.** From 6 to 12 months post-treatment PD reduction of ≥6mm pockets in the LANAP™ quadrant continued to improve from 2.49 to 2.94mm (Table 3). MWF declined slightly from 2.89mm to 2.78mm. These differences are well within normal variation and as the statistical analysis shows at 12-Mo the two procedures produce equivalent clinical outcomes (p = 0.99, Table 2).

However, LANAP™ is a much less invasive procedure than MWF. This is reflected in the discomfort scores. Although many people have difficulty localizing pain in the mouth, the subjects in this study were able to discriminate a significant difference in post-op discomfort between LANAP™ and MWF.

The LANAP™ quadrant also showed greater reduction in the percent of sites that bled on probing at both 6-Mo and 12-Mo. This could be the result of many possible processes in the LANAP quadrant such as improved or accelerated tissue regeneration,<sup>10,11</sup> improved neo-vascularization or immune activation.

**LANAP™ and MWF VS SRP.** The PD reductions of ≥6mm pockets in the CD and SRP quadrants were greater than expected<sup>13</sup> at 6-Mo: CD = 1.76 mm and SRP = 2.19 mm. There were sufficient factors enhancing control quadrant responses to account for the improvements: cross-over from active treatments, improved oral hygiene, full-mouth occlusal adjustment, the Hawthorn and “white coat” effects, laser placebo effect, and so on. However, PD reductions in the SRP quadrant continued to improve so that by 12-Mo SRP is equivalent to both MWF and LANAP™ (P=0.99 and P=0.95).

It would follow from these data that, in the long run (1 year) SRP provides equivalent clinical outcomes as both the MWF or the LANAP™ procedures. However probing depth is not the entire story. The CAL analysis may shed more light on the anomalous SRP data. There is also the possibility that there was some unanticipated systemic effect on the SRP pockets but not those treated with only CD. A primary difference between CD and SRP is that SRP produces a sub-gingival wound. There is strong evidence that laser irradiation can enhance wound healing through immune activation.<sup>14-17</sup> A testable hypothesis that is consistent with these data is that an aspect of the LANAP™ protocol generated a significant, positive and unanticipated systemic (or trans-oral) effect on sub-gingival wound healing.

## CONCLUSIONS

1. For Probing Depth reduction the LANAP™ protocol is equivalent to the Modified Widman Flap, for the treatment of advanced periodontitis.
2. LANAP™ resulted in a greater reduction in the percent of sites that bled when probed than the other three treatments.
3. Patients experience significantly less discomfort following LANAP™ than following MWF.
4. The data suggest the possibility that the LANAP™ protocol caused a systemic effect on sub-gingival wound healing that crossed over to adjacent quadrants.

## ACKNOWLEDGEMENTS

This study was supported by Millennium Dental Technologies, Inc., Cerritos, CA. David Harris and Bio-Medical Consultants received consulting fees from Millennium for their work on this project. Dawn Nicholson, Robert Gregg and Delwin McCarthy are Principals of Millenium. The other authors were investigators and have no financial interest in the outcome of this study. They were reimbursed for study expenses. Portions of this report were presented previously.<sup>18</sup>

## REFERENCES CITED

- [1] Neill, M.E., Mellonig, J.T. “Clinical efficacy of the Nd:YAG laser for combination periodontitis therapy,” *Pract. Periodontics Aesthet Dent.* 9(suppl),1-5 (1997).
- [2] Greenwell H, Harris, DM, Pickman, K, Burkart, J, Parkins, F, and Myers T., “Clinical evaluation of Nd:YAG laser curettage on periodontitis and periodontal pathogens,” *J. Dent. Res.* 78,138 (1999).
- [3] Gregg RH II, McCarthy DK, “Laser ENAP for periodontal bone regeneration,” *Dent. Today*17, 88-91(1998).
- [4] Gregg RH II, McCarthy DK, “Laser ENAP for periodontal ligament regeneration.” *Dent. Today*17,86-88 (1998).
- [5] Gregg RH II, McCarthy DK, “Laser periodontal therapy: case reports,” *Dent. Today* 20, 74-81 (2001).
- [6] Gregg RH II, McCarthy DK, “Laser periodontal therapy for bone regeneration,” *Dent. Today* 21, 54-59 (2002).



- [7] Harris DM, Gregg RH, McCarthy, DK, Colby, LE and Tilt LV, "Sulcular debridement with pulsed Nd:YAG," Proc. SPIE 4610, 49-58 (2002).
- [8] Harris DM, Gregg RH, McCarthy, DK, Colby, LE and Tilt LV, "Laser-assisted new attachment procedure in private practice." Gen. Dent. 52, 396-403 (2004).
- [9] Yukna RA, Evans GH, Vastardis S, and Carr, RL, "Human periodontal regeneration following the laser assisted new attachment procedure," Paper presented at: IADR/AADR/CADR 82nd General Session; March 10-13, 2004; Honolulu, HI. Abstract 2411.
- [10] Yukna RA, Carr RL, Evans GH, "Histologic evaluation of an Nd:YAG Laser-Assisted New Attachment Procedure in humans," International Journal of Periodontics & Restorative Dentistry 26, 577-587 (2007).
- [11] Nevins ML, Marcelo, C, Schupbach, P, Kim, S-W, Kim, DM, Nevins, M, "Human clinical and histologic evaluation of Laser-Assisted New Attachment Procedure. International Journal of Periodontics & Restorative Dentistry 32(5), 497-507 (2012).
- [12] Nevins ML, Kim S-W, Camelo M, Martin IS, Kim D, Nevins M, "A prospective 9-month human clinical evaluation of Laser-Assisted New Attachment Procedure (LANAP™) therapy," International Journal of Periodontics & Restorative Dentistry 34, 21-27 (2014).
- [13] Cobb CM, "Nonsurgical pocket therapy: Mechanical," Ann. Periodontol. 1, 443-490 (1996).
- [14] Anders JJ (Chair), "Photobiomodulation Session." 34<sup>th</sup> Annual Conference of the American Society of Lasers in Surgery and Medicine. Phoenix, (2013).
- [15] Byrnes KR, Barna L, Chenault VM, Waynant RW, Ilev IK, Longo L, Miracco C, Johnson B, Anders JJ, "Photobiomodulation improves cutaneous wound healing in an animal model of type II diabetes," Photomed. Laser Surg. 22(4), 281-90 (2004).
- [16] Byrnes KR, Waynant RW, Ilev IK, Wu X, Barna L, Smith K, Heckert R, Gerst H, Anders JJ, "Light promotes regeneration and functional recovery and alters the immune response after spinal cord injury," Lasers Surg. Med. 36(3), 171-85 (2005).
- [17] Tuner J, Hode L, [Laser Therapy: Clinical Practice and Scientific Background], Prima Books. Grangesberg, Sweden, 189-197 (2002).
- [18] Reynolds M., "LANAP™ Clinical Study: Update on the in-progress. university-based, five-center, prospective, randomized clinical trial," Amer Acad Periodontics 99<sup>th</sup> Annual Meeting, Philadelphia September (2013).